2 Sagittal Spinopelvic Parameters in Degenerative Lumbar Spinal Stenosis

Bhavuk Garg and Gururaj Sangondimath

Introduction

Sagittal balance is an essential biomechanical feature of the human spine, required to maintain center of gravity over a narrow zone between the two feet, which in turn ensures bipedalism in the most energy-efficient manner.[1] Dubousset[2] introduced the term "cone of economy," to describe an inverted cone with its apex at the feet and the base expanding cephalad. If the body remains inside the cone, the energy expenditure remains minimum and functioning is most efficient. If the patient loses sagittal balance, he/she moves out of this cone and his/her energy expenditure increases in proportion to the malalignment (**Fig. 2.1**).

Significant sagittal imbalance is not a common feature of lumbar spinal stenosis (LSS). However, it is not uncommon for patients to have a flat back because of multilevel degeneration or a stooped posture as a compensatory mechanism to relieve the pressure on the neural elements. When LSS is associated with degenerative scoliosis, loss of sagittal balance is much more common. Abnormalities in sagittal balance can clinically manifest with back pain due to abnormal loading mechanics and muscle fatigue. Restoration of normal sagittal balance is vital for optimal functional outcome and patient satisfaction in any surgical treatment for degenerative lumbar spinal stenosis.[3]

Sagittal Balance and Sagittal Vertical Axis

The sagittal vertical axis (SVA) is a measure of the global sagittal balance. Clinically, a person is said to be balanced in the sagittal plane, when the head is centered over the malleoli at the ankle. Radiologically, SVA is measured on a standing full-length lateral radiograph as the sagittal offset between a plum line dropped down from the C7 vertebral body. It normally intersects the posterosuperior corner of S1 or falls within 2.5 cm anterior or posterior to that point. If C7 plumb line is in front of posterosuperior corner of S1, it is called *positive alignment*, and if it is behind, it is called *negative*.[1] In patients with spinal kyphosis, the SVA tends to shift forward.

Spinopelvic Parameters

Realization of the importance of pelvis in overall sagittal alignment has led to coining of term "pelvic vertebrae," and a great amount of

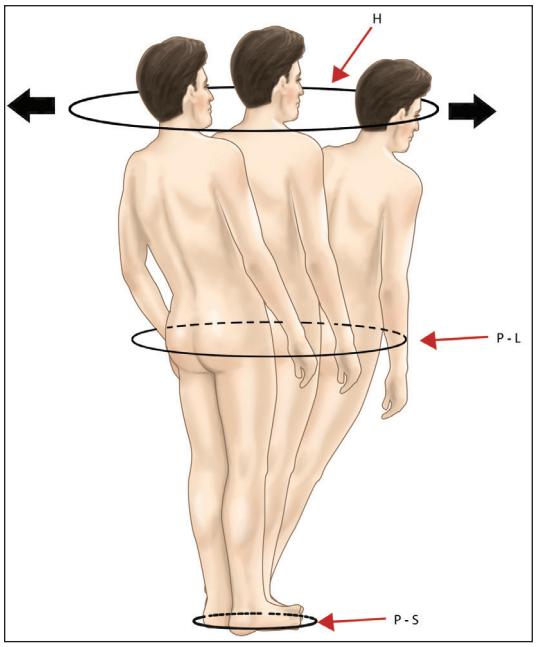

Fig. 2.1 Dubousset's cone of economy. The figure outlines the "stable" zone surrounding the individual that is conical in shape from the feet to the head. Deviation from the center within the zone results in greater muscular effort and energy expenditure to maintain an upright posture. Deviation of the body outside the cone results in falling or requiring support. H, head; P-L, pelvic level; P-S, polygon of sustentation.

research and understanding has evolved into various spinopelvic parameters. These spinopelvic parameters (**Fig. 2.2**) basically describe the relationship between pelvic morphology and sagittal spinal alignment. The three most important parameters are[1,4]:

1. *Pelvic incidence (PI)*: PI is a morphologic parameter, whose value is constant for a given individual, irrespective of the position of the pelvis. PI is defined as an angle between a perpendicular to the S1 sacral upper endplate and a line drawn from center of both femoral heads to the midpoint of S1 endplate. As sacroiliac joints have very limited mobility, PI remains a fixed value for a given individual.
2. *Pelvic tilt (PT)*: PT is the angle between a vertical line and a line drawn from center of femoral heads to the midpoint of upper sacral endplate. PT is basically a measurement of pelvic rotation (retroversion or anteversion) around the femoral heads. Increased PT means pelvic retroversion and decreased PT means pelvic anteversion.
3. *Sacral slope (SS)*: SS is measured as an angle between a horizontal line and upper sacral endplate.

PI is the sum of PT and SS, that is, PI = PT + SS. A vertical sacrum, that is, small SS due to pathology can lead to pelvic retroversion, resulting in increase in PT. Because PI is a fixed value for a given individual, PT and SS keep on changing depending on each other and are not reliable for planning of surgical treatment.[1]

PI strongly correlates with lumbar lordosis (LL) and a new parameter called PI − LL is often used to describe the amount of mismatch between pelvic morphology and lumbar curvature. Various studies have cited a value of PI − LL ≤ 10 degrees as a goal for spinopelvic sagittal alignment and this is often used for planning of surgical treatment.[1,5,6] Recently Schwab et al[7] have also stressed upon the role of thoracic kyphosis leading to a new equation to calculate ideal LL, LL = (PI + TK)/2 + 10. LL is usually measured by Cobb's method as an angle between upper endplate of L1 and upper sacral endplate. Similarly, thoracic kyphosis is measured between upper endplate of T4 and lower endplate of T12.[1,8] Pelvic shift is another

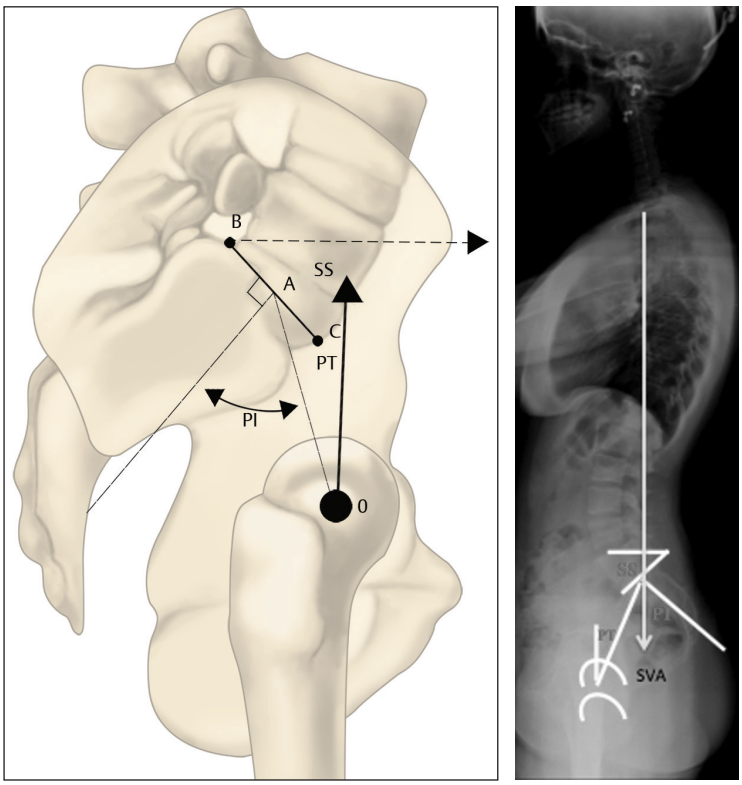

Fig. 2.2 Full-length lateral X-rays incorporating both proximal femurs is essential to measure spinopelvic parameters. Pelvic incidence (PI), pelvic tilt (PT), sacral slope (SS), lumbar lordosis, and sagittal vertical axis (SVA) are important sagittal parameters.

parameter that measures the distance between a vertical line from posterosuperior corner of S1 and heels.[9]

It is important to have full cassette 36 inches anteroposterior and lateral X-rays of whole spine including both femoral heads to measure these parameters correctly. Ideally the patient should stand in a freestanding position without any external support with both the hands on ipsilateral clavicle with the elbows and wrists flexed.[1,10] The hips and knees must be in neutral position and not flexed.

These spinopelvic parameters in combination help understand various compensatory mechanisms as well as help in planning treatment for several spinal disorders. Several studies have proved the relationship between these sagittal radiological parameters and improvement in quality of life, patient satisfaction, and clinical benefits.[6,11–14]

Normal Values of Sagittal Spinopelvic Parameters

The values of these parameters are quite variable in normal asymptomatic population and are also position dependent for several parameters. Mac-Thiong et al[15] measured these parameters in a large sample size of 709 normal patients and reported following values for these spinopelvic parameters: PT (13.0 ± 6.8 degrees, 2 standard deviation [SD]), SS (39.6 ± 7.9 degrees, 2 SD), and PI (52.6 ± 10.4 degrees, 2 SD) (**Table 2.1**).

Schwab et al recommended PI − LL within 10 degrees, SVA < 4 cm, and a PT < 20 degrees as the target of any surgical treatment for optimal sagittal balance.[16] Some studies also point out the variation in these parameters according to age and that these targets should be more stringent in younger patients.[1,17] Lim and Kim[18] reported that PI is similar in patients with LSS and normal population as compared with degenerative spondylolisthesis in which usually PI is significantly higher.

Table 2.1 Normal values of pelvic parameters[15]

Parameters	Normal values
Pelvic tilt	13.0° ± 6.8°
Sacral slope	39.6° ± 7.9°
Pelvic incidence	52.6° ± 10.4°

Normal Variations between Standing and Sitting

Realization of the fact that most people in today's world spend most of their time in sitting posture, analysis, and understanding of these radiologic parameters in sitting posture is also gaining importance. In a natural sitting position, lumbar spine assumes a kyphotic profile and lumbar spine along with thoracic spine forms a C-shaped sagittal curve. This is accompanied by anterior shifting of SVA as well as increase in cervical lordosis and PT. These findings are important as they may explain some failures in well-aligned lordotic postoperative spines, as a well-fused lordotic spine may not be biomechanically normal for sitting posture.[19] This area requires further research and well-designed studies.

Alteration of Sagittal Parameters in Lumbar Spinal Stenosis

Lumbar Degenerative Disk Disease without Instability

With progressive disk degeneration within the lumbar spine, there is a loss of disk height, which eventually results in loss of segmental lordosis. The initial compensation for the reduction in LL comes from hyperextension at other lumbar segments, retrolisthesis, and then retroversion of the pelvis, that is, increase in PT and reduction in SS. Usually, this compensation is sufficient. In patients with moderate to severe imbalance, other compensatory mechanisms such as decreased thoracic kyphosis, flexion of the hip and knee, and ankle extension also come into play (**Fig. 2.2**).[20]

Patients with lumbar degenerative disk disease (LDDD) or lumbar disk herniation (LDH) were found to have a lower PI value. Because the PI is constant for a particular individual, a low PI may be a predisposing factor for LDDD. A mismatch of > 10 degrees between PI and LL is

an indicator of significant sagittal malalignment. In such patients, one must actively look for compensation at the pelvis, hips, knees, and ankles[1] (**Fig. 2.3**).

Patients with LSS often develop a forward stoop to relieve neural compression. This is seen as sagittal malalignment radiologically. Decompression of neural elements alone may correct the stoop, and thereby the sagittal malalignment. Farrokhi et al[21] reported that increased sagittal imbalance and decreased LL and SS are common findings in LSS patients, when compared with normal healthy individuals. The treating surgeon should aim at correction of sagittal parameters, as well as the compensatory mechanisms to increase the energy efficiency.[18,22]

Lumbar Spinal Stenosis with Degenerative Spondylolisthesis

PI is found to be higher in people with degenerative spondylolisthesis as compared with individuals with only LDDD/LSS. It is postulated that the higher PI is a predisposing factor for development of degenerative spondylolisthesis. They also show higher PT and low SS values, thus indicating pelvic compensation.[23]

The surgical management of degenerative spondylolisthesis remains controversial, and there is no uniform agreement regarding the need for correcting sagittal alignment in every case. Although well-powered studies are lacking on this aspect, some systematic reviews have concluded that restoration of LL and sagittal balance may not offer any significant clinical benefit.[24] Gille et al[25] proposed a classification to help in surgical planning for patients with degenerative spondylolisthesis. They classified these patients into five groups:

- Type 1 preserved segmental lordosis (> 5 degrees) and preserved LL (LL > PI – 10 degrees): No need to restore segmental lordosis; simple posterior fusion without any interbody cage may be enough.
- Type 2 decreased segmental lordosis (< 5 degrees) but preserved LL (LL > PI – 10 degrees): Requires interbody fusion

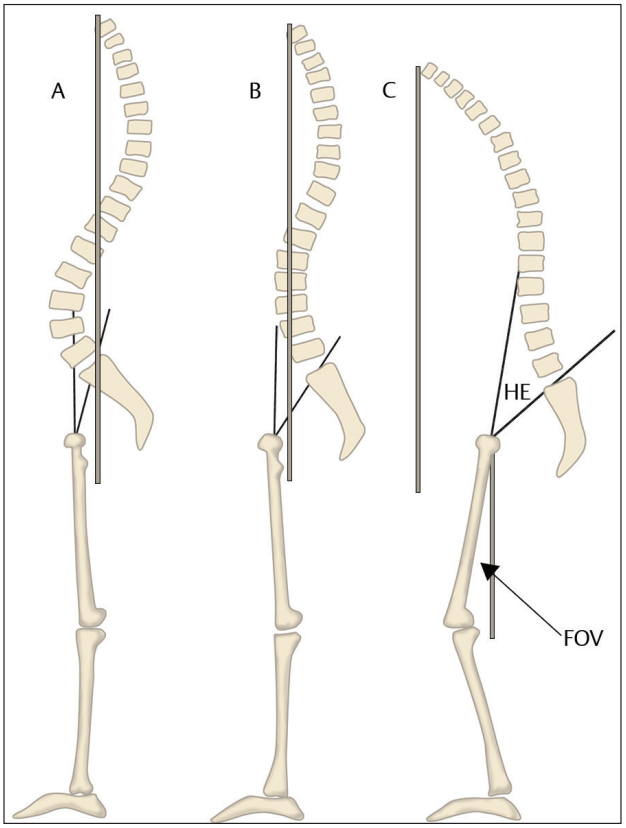

Fig. 2.3 Compensation of spinal imbalance in degenerative spinal disorders. A. Normal balance. B. Loss of lumbar lordosis and sagittal imbalance compensated by pelvis retroversion. C. Neuromuscular control and pelvis retroversion are not sufficient to compensate sagittal imbalance, and the patient bends knees to bring back as posteriorly as possible the C7 plumb line. FOV, femur obliquity with vertical; HE, hip extension.

with help of a cage to restore segmental lordosis.

- Type 3 decreased LL (LL < PI – 10 degrees): Usually short constructs are enough.
- Type 4 decreased LL (LL < PI – 10 degrees) with compensation to maintain sagittal balance (PT > 25 degrees): Usually requires an extended construct from L3–S1.
- Type 5 sagittal imbalance (SVA > 4 cm): Correction of sagittal deformity is more important than treatment of listhesis and requires long instrumentation.

Retrolisthesis above a spondylolisthesis is also being frequently reported either as a preoperative finding or as a result of adjacent segment disease postoperatively. Preoperatively a higher slip angle and degenerative disk disease at level above the slip have been reported as a risk factor for retrolisthesis.[26] There are no guidelines available regarding inclusion of retrolisthesis level in fusion mass in every case; however, an unstable retrolisthesis and sagittal imbalance may guide toward fusion of retrolisthesis segment.[27]

Multilevel Lumbar Spinal Stenosis/Lumbar Degenerative Disk Disease and Degenerative Scoliosis/Kyphosis

Sagittal imbalance is usually secondary to loss of LL, resulting from segmental disk degeneration and loss of disk height. This loss of LL further leads to positive sagittal imbalance meaning that center of gravity line moves more anterior in relation to the spinal column. Pelvis tries to compensate for this by retroversion leading to increased PT and decreased SS.[28]

Sagittal imbalance in degenerative scoliosis can be classified into type I or II. Type I include patients who are globally balanced but in whom a segmental portion of the spine is flat or kyphotic. In contrast, type II sagittal imbalance describes global and segmental imbalance. When sagittal and coronal imbalances coexist, they are divided into type A or B. With type A imbalance, the patient's shoulders and pelvis are tilted in opposite directions. Conversely, with type B imbalance, both the shoulders and the pelvis tilt in the same direction.[29] Type II A or B imbalances usually require longer instrumentation.

Most important pelvic parameter in degenerative scoliosis is high preoperative PT, reflecting pelvic retroversion for compensation. A high PT is correlated with poor clinical outcome, quality of life, and complications after surgery. Preoperative PT ≥ 26 degrees is considered to be a significant risk factor for complications.[30]

The most important parameter in the treatment of degenerative scoliosis is to maintain sagittal balance so that the head is directly above the pelvis. This causes decreased energy requirements on walking, limits pain and fatigue, improves cosmesis, patient satisfaction, and limits complications associated with unresolved (or new) deformities.[11,31]

Surgical Planning for Lumbar Spinal Stenosis Based on Sagittal Spinopelvic Parameters

Correlation between Postoperative Outcome of Lumbar Spinal Stenosis and Importance of Restoration of Sagittal Balance

Multilevel spinal fusion in patients with LSS may result in loss of LL (flat back). Compensation usually occurs in the form of pelvic retroversion, with decreased SS and increased PT, compared with normal theoretical values for the same PI.[28] Increased PT after surgery is strongly correlated with postoperative pain.[32] To prevent/reverse pelvic retroversion and reduce the PT, it is vital to achieve adequate restoration of LL (PI − LL < 10 degrees). Hence, it is vital to estimate the amount of LL that is required for optimal sagittal balance, prior to surgery. A high PI requires achieving more LL for sagittal balance. Even after surgery, most of these patients are under corrected as surgery is more technically challenging.

Lumbar Spinal Stenosis without Instability

Significant improvement in sagittal parameters may be achieved with decompression alone. In a recent study by Shin et al,[3] sagittal imbalance normalized in 73% of patients, 12 months after simple decompression surgery for LSS. Hence, not all patients with LSS without instability require additional fusion/realignment procedures. Old age, PI – LL mismatch, higher disability scores, high PT, low thoracic kyphosis, and presence of spondylolisthesis favor a realignment surgery rather than a simple decompression.[3] Hikata et al[33] reported that patients with SVA > 80 mm had residual imbalance and a poor clinical outcome after decompression only surgery for LSS. In other studies, preoperative SVA did not correlate with clinical outcomes.[3,33]

Suzuki et al[22] divided LSS patients into claudication type and radicular pain only type. They reported that claudication-type patients have more sagittal imbalance, less LL, and larger PT, which necessitates a more stringent assessment of sagittal parameters. Patients who complain of poor posture/back pain are also probable candidates for realignment surgery.

Patients with LSS have an increased tendency to fall. Although decompression alone has been shown to decrease this tendency as a result of improved walking and balancing, restoration of sagittal parameters has shown an even better improvement in this tendency to fall.[1] Positive sagittal balance has been reported the worst radiographic parameter associated with poor health outcome. Hence correction of positive balance is important whenever a fusion surgery is planned in a patient with LSS.[31]

Different surgical techniques such as laminectomy, minimally invasive surgical techniques, such as unilateral laminotomy, bilateral laminotomy, and split-spinous process laminotomy have not shown any statistical significant difference in improvement of sagittal parameters and clinical outcome.[34]

Lumbar Spinal Stenosis with Degenerative Listhesis

Importance of maintaining the sagittal alignment is much more when fusion is added to decompression surgery. Kim et al[35] were the first to evaluate the impact of fusion for degenerative spondylolisthesis, on the sagittal balance. They reported that patients in whom PT improved after fusion achieved good clinical outcomes. However, a recent systematic review by Rhee et al[24] concluded that restoration of focal LL and sagittal balance for single-level lumbar degenerative spondylolisthesis does not seem to yield clinical improvements.

Lumbar Spinal Stenosis with Degenerative Scoliosis/Kyphosis

In degenerative scoliosis, sagittal balance must always be taken into account for good clinical outcome. High preoperative PT, reflecting preoperative retroversion for compensation, is correlated with poor clinical outcome, quality of life, and complications after surgery.[36–38] **Fig. 2.4** shows the preoperative radiographs and MRI, and **Fig. 2.5** shows the postoperative radiographs demonstrating an improvement in the sagittal parameters in a patient of LSS with severe lumbar kyphosis (**Table 2.2**).

Adjacent-Segment Degeneration and Sagittal Balance

Studies have suggested that abnormal balance plays a significant role in degeneration of adjacent segments after lumbar spinal fusion.[39] Patients with decreased SS and /or abnormal C7 plumb line after spinal fusion have higher rate of adjacent-segment degeneration.

Table 2.2 Pre- and postoperative sagittal parameters (Figs. 2.4, 2.5)

	Pelvic incidence	Pelvic tilt	Sacral slope	Lumbar lordosis	SVA
Preoperative	50°	32°	18°	+13°	+8 cm
Postoperative	50°	12°	38°	−45°	0

Abbreviation: SVA, sagittal vertical axis.

Fig. 2.4 X-ray and MRI showing loss of lumbar lordosis, pelvic retroversion, hyperextension, discal degeneration, and retrolisthesis in a patient with severe lumbar spinal stenosis.

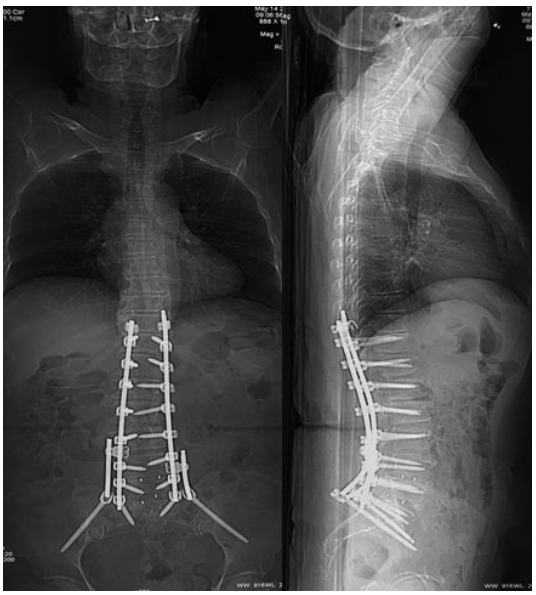

Fig. 2.5 Restoration of lumbar lordosis and normal pelvic tilt/sacral slope through posterior instrumentation and use of interbody cages in the same patient as in **Fig. 2.3**. (Comparative angles in **Table 2.2.**)

Risk Factors for Postoperative Sagittal Imbalance

Studies suggest that preoperative assessment of sagittal parameters is important to prevent overt sagittal imbalance postoperatively. This is especially required in patients with high PI as greater correction of LL is required to achieve balanced spine. The amount of LL to be achieved can be calculated by using formula LL = PI ± 9 degrees.[24] Postoperative imbalance is worse than preoperative as it is fixed and compensatory mechanisms do not work that effectively in an instrumented spine.

Summary

Sagittal balance allows a person to function within the cone of efficiency, where energy expenditure for gait, maintaining posture, and performing activities of daily living, is minimum. A positive sagittal balance (SVA > 50 mm), is associated with increased energy expenditure when maintaining an upright posture, and during normal function. This may result in back pain, easy fatigability and imbalance resulting in a tendency to fall.

In patients with simple LSS without instability or with accompanying single-level degenerative spondylolisthesis, significant imbalance is usually not a problem. However, significant multilevel LDDD or degenerative scoliosis that may occur along with LSS may result in loss of LL, resulting in compensation from the pelvis, hips, knees, and ankles. In these patients, restoration of LL by sagittal realignment procedures is crucial.

Most of the current literature points toward a direct relationship between sagittal spinopelvic parameters and patient-reported outcomes and satisfaction rates. These parameters help plan and deliver customized treatment to each individual. Consideration of these parameters in surgical planning has witnessed a paradigm shift in the surgical management of LSS. Various software such as "Surgimap" are available, which provide a highly accurate assessment of these parameters and are quite valuable in strategic planning for these patients.[40]

Pearls

- Sagittal balance is vital for efficient posture, gait, and function.
- Loss of sagittal balance results in back pain, poor posture, inefficient gait, and imbalance with a tendency to fall.
- Clinically, sagittal balance indicates that the head is centered over the pelvis and the ankles, with the hips, knees, and ankles in neutral position.
- A standing full-length radiograph that includes the whole spine and the proximal femora must be obtained, with the hips and knees in neutral position.
- Sagittal balance is assessed using the SVA, LL, thoracic kyphosis, PI, PT, and SS.
- In degenerative LSS without deformity or instability, simple decompression is sufficient.
- Preoperative SVA > 80 mm, PT > 26 degrees, PI – LL > 10 degrees, and low thoracic lordosis usually point toward need for realignment surgery.
- Use of specialized software such as "Surgimap" makes assessment of these parameters quite easy and accurate.

Pitfalls

- Do not rely on a single parameter alone to analyze the sagittal imbalance.
- Patients with severe sagittal imbalance with failed compensatory mechanisms may not benefit from simple decompression.
- Ignorance of the natural changes in spinopelvic parameters occurring while sitting may explain some of the failures seen with lumbar fusion surgeries.

References

1. Diebo BG, Varghese JJ, Lafage R, Schwab FJ, Lafage V. Sagittal alignment of the spine: what do you need to know? Clin Neurol Neurosurg 2015;139:295–301
2. Dubousset J. Three-dimensional analysis of the scoliotic deformity. In: Weinstein S, ed. The Pediatric Spine: Principles and Practice. New York, NY: Raven Press; 1994:479–496
3. Shin EK, Kim CH, Chung CK, et al. Sagittal imbalance in patients with lumbar spinal stenosis and outcomes after simple decompression surgery. Spine J 2017;17(2):175–182
4. Legaye J, Duval-Beaupère G, Hecquet J, Marty C. Pelvic incidence: a fundamental pelvic parameter for three-dimensional regulation of spinal sagittal curves. Eur Spine J 1998;7(2):99–103
5. Vialle R, Levassor N, Rillardon L, Templier A, Skalli W, Guigui P. Radiographic analysis of the sagittal alignment and balance of the spine in asymptomatic subjects. J Bone Joint Surg Am 2005;87(2):260–267
6. Schwab F, Patel A, Ungar B, Farcy JP, Lafage V. Adult spinal deformity-postoperative standing imbalance: how much can you tolerate? An overview of key parameters in assessing alignment and planning corrective surgery. Spine 2010;35(25):2224–2231
7. Schwab FJ, Diebo BG, Smith JS, et al. Fine-tuned surgical planning in adult spinal deformity: determining the lumbar lordosis necessary by accounting for both thoracic kyphosis and pelvic incidence. Spine J 2014;14:S73
8. Roussouly P, Gollogly S, Berthonnaud E, Dimnet J. Classification of the normal variation in the sagittal alignment of the human lumbar spine and pelvis in the standing position. Spine 2005;30(3):346–353
9. Galbusera F, Lovi A, Bassani T, Brayda-Bruno M. MR imaging and radiographic imaging of degenerative spine disorders and spine alignment. Magn Reson Imaging Clin N Am 2016;24(3):515–522

10. Horton WC, Brown CW, Bridwell KH, Glassman SD, Suk SI, Cha CW. Is there an optimal patient stance for obtaining a lateral 36" radiograph? A critical comparison of three techniques. Spine 2005;30(4):427–433
11. Schwab F, Lafage V, Farcy J-P, et al. Surgical rates and operative outcome analysis in thoracolumbar and lumbar major adult scoliosis: application of the new adult deformity classification. Spine 2007;32(24):2723–2730
12. Terran J, Schwab F, Shaffrey CI, et al; International Spine Study Group. The SRS-Schwab adult spinal deformity classification: assessment and clinical correlations based on a prospective operative and nonoperative cohort. Neurosurgery 2013;73(4): 559–568
13. Blondel B, Schwab F, Ungar B, et al. Impact of magnitude and percentage of global sagittal plane correction on health-related quality of life at 2-years follow-up. Neurosurgery 2012;71(2): 341–348, discussion 348
14. Smith JS, Klineberg E, Schwab F, et al; International Spine Study Group. Change in classification grade by the SRS-Schwab Adult Spinal Deformity Classification predicts impact on health-related quality of life measures: prospective analysis of operative and nonoperative treatment. Spine 2013;38(19):1663–1671
15. Mac-Thiong JM, Roussouly P, Berthonnaud E, Guigui P. Ageand sex-related variations in sagittal sacropelvic morphology and balance in asymptomatic adults. Eur Spine J 2011; 20(Suppl 5):572–577
16. Schwab F, Ungar B, Blondel B, et al. SRS-Schwab adult spinal deformity classification: a validation study. Spine 2012;37:1077–1082
17. Schwab FJ, Lafage R, Liabaud BB, et al. Doesone size fit all? Defining spinopelvic alignment thresholds based on age. Spine J 2014;14:S120–S121
18. Lim JK, Kim SM. Comparison of sagittal spinopelvic alignment between lumbar degenerative spondylolisthesis and degenerative spinal stenosis. J Korean Neurosurg Soc 2014;55(6): 331–336
19. Hey HW, Wong CG, Lau ET, et al. Differences in erect sitting and natural sitting spinal alignment-insights into a new paradigm and implications in deformity correction. Spine J 2017;17(2): 183–189
20. Buckland AJ, Vira S, Oren JH, et al. When is compensation for lumbar spinal stenosis a clinical sagittal plane deformity? Spine J 2016;16(8): 971–981
21. Farrokhi MR, Haghnegahdar A, Rezaee H, Sharifi Rad MR. Spinal sagittal balance and spinopelvic parameters in patients with degenerative lumbar spinal stenosis; a comparative study. Clin Neurol Neurosurg 2016;151:136–141
22. Suzuki H, Endo K, Kobayashi H, Tanaka H, Yamamoto K. Total sagittal spinal alignment in patients with lumbar canal stenosis accompanied by intermittent claudication. Spine 2010;35(9): E344–E346
23. Barrey C, Roussouly P, Perrin G, Le Huec JC. Sagittal balance disorders in severe degenerative spine. Can we identify the compensatory mechanisms? Eur Spine J 2011;20(Suppl 5):626–633
24. Rhee C, Visintini S, Dunning CE, Oxner WM, Glennie RA. Does restoration of focal lumbar lordosis for single level degenerative spondylolisthesis result in better patient-reported clinical outcomes? A systematic literature review. J Clin Neurosci 2017;44:95–100
25. Gille O, Challier V, Parent H, et al; French Society of Spine Surgery (SFCR). Degenerative lumbar spondylolisthesis: cohort of 670 patients, and proposal of a new classification. Orthop Traumatol Surg Res 2014;100(6, Suppl):S311–S315
26. Mehta JS, Kochhar S, Harding IJ. A slip above a slip: retrolisthesis of the motion segment above a spondylolytic spondylolisthesis. Eur Spine J 2012;21(11):2128–2133
27. Takenaka S, Tateishi K, Hosono N, Mukai Y, Fuji T. Preoperative retrolisthesis as a risk factor of postdecompression lumbar disc herniation. J Neurosurg Spine 2016;24(4):592–601
28. Barrey C, Jund J, Noseda O, Roussouly P. Sagittal balance of the pelvis-spine complex and lumbar degenerative diseases. A comparative study about 85 cases. Eur Spine J 2007;16(9):1459–1467
29. Bridwell KH. Adult spinal deformity revision surgery. In: Heary RF, Albert TJ, eds. Spinal Deformity: The Essentials. 1st ed. New York, NY: Thieme; 2007:240e–248
30. Le Huec JC, Faundez A, Dominguez D, Hoffmeyer P, Aunoble S. Evidence showing the relationship between sagittal balance and clinical outcomes in surgical treatment of degenerative spinal diseases: a literature review. Int Orthop 2015; 39(1):87–95
31. Lee BH, Park JO, Kim HS, et al. Spinal sagittal balance status affects postoperative actual falls and quality of life after decompression and fusion in-situ surgery in patients with lumbar spinal stenosis. Clin Neurol Neurosurg 2016;148:52–59
32. Gottfried ON, Daubs MD, Patel AA, Dailey AT, Brodke DS. Spinopelvic parameters in postfusion flatback deformity patients. Spine J 2009;9(8): 639–647
33. Hikata T, Watanabe K, Fujita N, et al. Impact of sagittal spinopelvic alignment on clinical outcomes after decompression surgery for lumbar spinal canal stenosis without coronal imbalance. J Neurosurg Spine 2015;23(4):451–458
34. Machado GC, Ferreira PH, Harris IA, et al. Effectiveness of surgery for lumbar spinal

stenosis: a systematic review and meta-analysis. PLoS One 2015;10(3):e0122800
35. Kim MK, Lee SH, Kim ES, Eoh W, Chung SS, Lee CS. The impact of sagittal balance on clinical results after posterior interbody fusion for patients with degenerative spondylolisthesis: a pilot study. BMC Musculoskelet Disord 2011;12:69
36. Charosky S, Guigui P, Blamoutier A, Roussouly P, Chopin D; Study Group on Scoliosis. Complications and risk factors of primary adult scoliosis surgery: a multicenter study of 306 patients. Spine 2012;37(8):693–700
37. Lafage V, Schwab F, Patel A, Hawkinson N, Farcy JP. Pelvic tilt and truncal inclination: two key radiographic parameters in the setting of adults with spinal deformity. Spine 2009;34(17):E599–E606
38. Johnson RD, Valore A, Villaminar A, Comisso M, Balsano M. Pelvic parameters of sagittal balance in extreme lateral interbody fusion for degenerative lumbar disc disease. J Clin Neurosci 2013;20(4):576–581
39. Kumar MN, Baklanov A, Chopin D. Correlation between sagittal plane changes and adjacent segment degeneration following lumbar spine fusion. Eur Spine J 2001;10(4):314–319
40. Akbar M, Terran J, Ames CP, Lafage V, Schwab F. Use of Surgimap spine in sagittal plane analysis, osteotomy planning, and correction calculation. Neurosurg Clin N Am 2013;24(2):163–172